

She was born to a third-degree consanguineously married couple with a G2A1 mother with unremarkable antenatal and family history. She had poor respiratory effort during perinatal period requiring 1 min of positive pressure ventilation and was later stabilized on continuous positive airway pressure. An umbilical venous catheter was secured in the neonatal intensive care unit. At 1 hour of life, capillary blood glucose (CBG) was low for which 2 mL/kg of 10% dextrose bolus was administered and was followed by glucose infusion rate (GIR) at a rate of 5 mg/kg/min. Subsequently, GIR was escalated to 15 mg/kg/min within 4 Hour of life with a mean blood glucose level of 24 mg/dL. Enteral feeds started on day 3 with pasteurized donor human milk along with the mother's milk. In view of refractory hypoglycemia, critical blood samples on day 5 of life unveiled hyperinsulinemia (88.42 IU/mL by electrochemiluminescence immunoassay [ECLIA] assay) and levels of growth hormone (1.44 ng/mL) and cortisol (51.24 µg/dL by ECLIA assay) were normal. Subsequently, the baby developed sepsis due to central line associated bloodstream infection (CLABSI), and *Klebsiella pneumoniae* was isolated from blood culture. Even though she was a premature baby and had CLABSI and culture-positive sepsis, the very high GIR requirement was suggestive of a severe form of HH.

In view of hyperinsulinism, treatment with diazoxide, and hydrochlorothiazide were initiated on day 5, and dosage was incremented to 25 mg/kg/day and 2 mg/kg/day, respectively. The GIR could not be brought down despite a high dose of diazoxide with hydrochlorothiazide. Hence, diazoxide unresponsive hypoglycemia was suspected. Genetic workup for *ABCC8* and *KCNJ11* mutation analysis was done. Oral hydrocortisone 2 mg/kg/day was started and enteral feeding was established by day 10 of life. On day 12 of life, the baby had symptomatic hypoglycemia with a maximum GIR of 32 mg/kg/min. Hence, an intravenous (IV) infusion of glucagon 5 µg/kg/h was considered and titrated accordingly with a maximum requirement of 17 µg/kg/h. Octreotide was initially not given due to an increased risk of necrotizing enterocolitis, especially in a preterm neonate.

After an unsuccessful trial of oral nifedipine 0.5 mg/kg/day on day 14 for persistent hypoglycemia, we started subcutaneous (SC) octreotide, weighing the risk versus benefit, at a dose of 3 µg/kg/dose every 6 hours and subsequently increased to 10 µg/kg/dose. The baby responded to SC octreotide and GIR was reduced to 4–6 mg/kg/min. On day 24, the baby had another culture-positive *Enterococcus faecalis* infection and was treated with antibiotics. On day 34, genetic analysis revealed a homozygous mutation of *ABCC8* at location exon 36 with a pathogenic variant (c.4353G>A). This confirmed the diagnosis of familial HH type 1 (HHF1) with autosomal recessive (AR) inheritance. As the AR inheritance with biallelic mutations of potassium ATP channels consistently presents as a diffuse lesion affecting all pancreatic beta cells, a 18F-DOPA PET scan

was considered unnecessary for differentiating between focal and diffuse lesions.

Except for SC octreotide and glucagon infusion, all other medications were stopped subsequently. On day 42, the baby had *Enterobacter cloacae* sepsis and the baby was administered antibiotics for ten days. Glucagon infusion was stopped on day 47 of life. A multidisciplinary team meeting was conducted and the decision was made to perform a near-total pancreatectomy. Before surgery, octreotide was not stopped considering the labile glycaemic status.

The baby underwent a laparoscopic near-total pancreatectomy on day 50 which was uneventful. Histopathology (H&E) of the specimen exhibited a group of islet cells with a few of them having abundant eosinophilic cytoplasm and large nuclei [Figure 1]. Immunohistochemistry (IHC) was positive for synaptophysin, chromogranin, and insulinoma-associated protein 1 [Figure 2]. The above H&E and IHC features represent a diffuse form of congenital hyperinsulinism (CHI).

Magnetic resonance imaging of the brain, retinopathy of prematurity screening, and hearing screening were normal. As an emergency drug, SC administration of glucagon was recommended when glucose levels were low and the baby could not feed. The baby was discharged and was advised to review when glucose levels were more than 300 mg/dL or low. Figure 3 illustrates the clinical course and management of the baby. On follow-up at 6 months of corrected gestational age, Developmental Assessment Scales for Indian Infant's Evaluation showed that the baby had mild developmental delay corresponding to 5 months. Parents were extensively counseled regarding the need for genetic testing as well as the

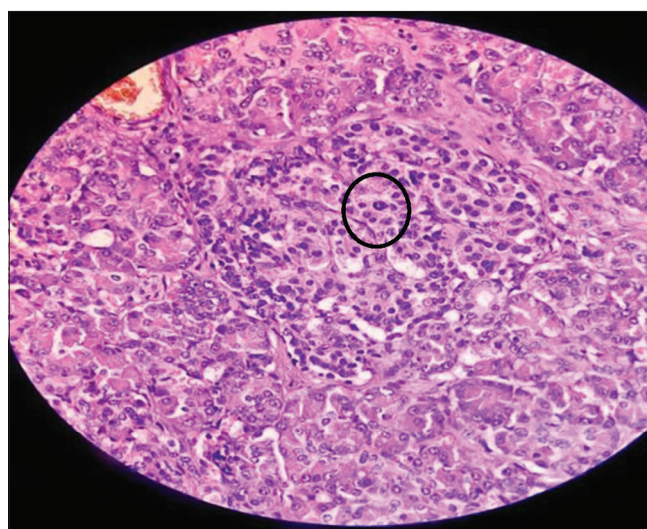


Figure 1: Histopathology of pancreatic specimen showing a group of islet cells demonstrating abundant eosinophilic cytoplasm and nucleomegaly.

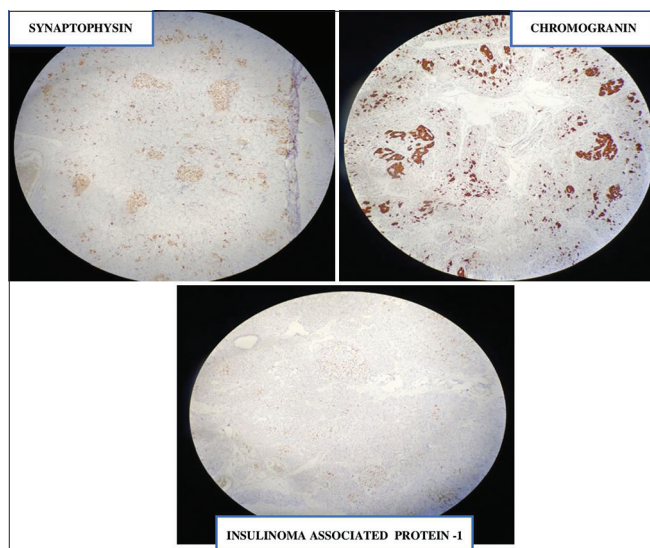


Figure 2: Immunohistochemistry of β -cells of pancreas-positive for neuroendocrine markers.

risk of recurrence in subsequent pregnancies. However, the couple was not willing to do the genetic testing.

DISCUSSION

HH is an important cause of refractory hypoglycemia in neonates, characterized by excessive insulin secretion from the pancreatic β -cells.^[2] HH can present as transient, prolonged, or persistent (congenital) forms. Infants who are small for gestational age or born to diabetic mothers face an increased risk of hypoglycemia, which can lead to irreversible neuronal injury. Hence, prompt recognition and treatment are of paramount importance.^[3,4]

The disorders with AR inactivating mutations in the *ABCC8* and *KCNJ11* genes, which encode the two subunits of the ATP-sensitive K^+ channel in pancreatic β -cells, are responsible for the most severe forms of hyperinsulinemia.^[5] Neonates with these KATP channel mutations present with severe hypoglycemia, large-for-gestational-age birth weight, and high GIR requirements which were noticed in our baby.

Knowledge of genetic mutations, the evolution of advanced imaging techniques such as 18F-Fluorodihydroxyphenylalanine positron emission computed tomography (18F-DOPA PET) scans, and the capability to histologically differentiate between focal and diffuse forms of persistent HH have substantially improved and streamlined its treatment. If hypoglycemia fails to respond to diazoxide, molecular testing for HH becomes imperative. Our baby's genetic analysis showed a homozygous mutation of *ABCC8* at location exon 36 with a pathogenic variant (c.4353G>A) with AR inheritance.

Differentiation into focal and diffuse forms of confirmed cases of HH using an 18f-DOPA PET scan is quite essential in making a surgical decision. The diffuse lesion is the most severe form involving all the β -cells in the pancreas. This has an AR inheritance and is caused by biallelic mutations in one of the KATP channel genes. The cause for dominant KATP-HH is the monoallelic mutation in the KATP channel genes which usually have a milder presentation, and patients often respond to diazoxide.^[6] The focal lesion is due to monoallelic mutation in one of the KATP channel genes and is paternally inherited. When the genetic analysis is consistent with diffuse disease, 18F-DOPA PET/CT is not indicated, which requires significant radiation exposure and anesthesia.^[7] Hence, in our case, the DOPA scan was deferred as AR inheritance was confirmed.

In order to maintain euglycemia, frequent feeds through a nasogastric tube or gastrostomy are required in patients with HH. To overcome symptomatic hypoglycemia and reconstitute normoglycemia, a "minibolus" of IV 10% dextrose at a dosage of 2 mL/kg is administered. Subsequently, the GIR is sequentially tailored according to blood glucose levels, employing higher concentrations of IV glucose. Diazoxide, octreotide, nifedipine, glucagon, and hydrocortisone have been tried in treating HH. The use of hydrocortisone and nifedipine, as an acute treatment of hypoglycemia, has limited evidence.^[8,9]

Glucagon increases blood glucose levels by inducing glycogenolysis, and gluconeogenesis and inhibits glycolysis and glycogenesis. It can be administered via IV, SC, or intramuscular (IM) routes.^[10] There is little information available on the use of IV infusion of glucagon in the treatment of neonatal hypoglycemia. In our case, we used glucagon as a continuous infusion which helped in bringing down the GIR.

Sirolimus, an inhibitor of the mammalian target of rapamycin, has been utilized as an ultimate therapeutic measure in HH to surpass the need for surgical intervention. In view of a preterm baby with sepsis, considering the risk versus benefit, sirolimus was not tried in our baby.

The primary reasons that impact the decision for the surgery are the need for high GIR and the absence of response to medications. All medications should be completely stopped before surgery as they may interfere with histological diagnosis.^[11] In our baby, except for SC octreotide, all other drugs were stopped before surgery. Focal lesions are cured by laparoscopic excision while diffuse lesions mandate near-total pancreatectomy for effective management.^[12] In our case, a laparoscopic near-total pancreatectomy was performed.

During the immediate postoperative period, certain babies may present with transient hyperglycemia that may require the administration of insulin. In our case, the baby continued to require SC octreotide to maintain

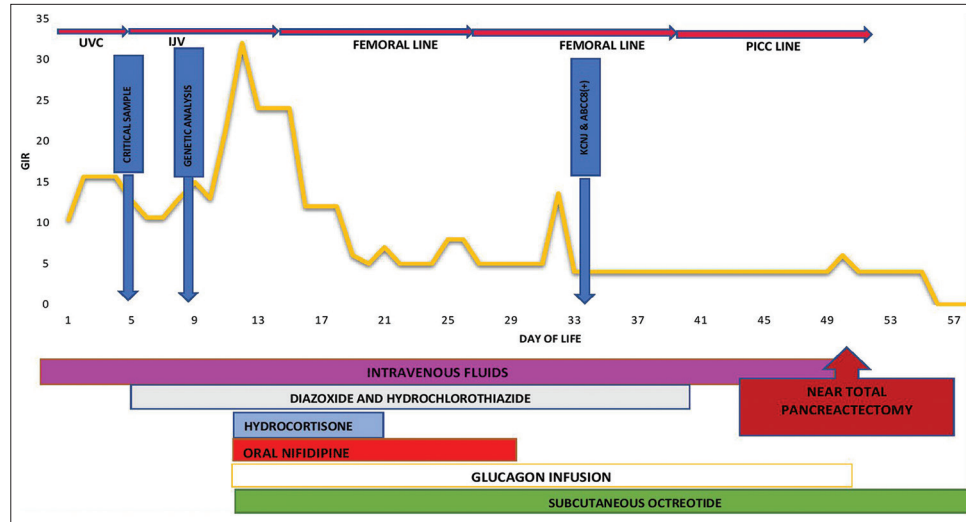


Figure 3: Clinical course and treatment of the baby. GIR: glucose infusion rate, UVC: Umbilical venous catheter, IJV: Internal jugular vein, PICC: Peripherally inserted central venous catheter.

CBG levels. Research findings have shown that following near-total pancreatectomy, 60% of children experienced ongoing hypoglycemia necessitating medical interventions. Furthermore, the incidence of insulin-dependent diabetes mellitus reached 96% at 11 years post-surgery.^[13,14] Infants on treatment for CHI should have long-term developmental follow-up due to the high risk of neurodevelopmental delay, cerebral palsy, diabetes, and epilepsy.^[15,16]

CONCLUSION

Early diagnosis and aggressive management of HH is the cornerstone for the prevention of hypoglycemia-induced brain injury. Molecular evaluation is mandatory in any case of diazoxide unresponsive hypoglycemia for effective management of refractory hypoglycemia. Continuous IV glucagon infusion can help reduce the GIR. An 18F-DOPA PET scan can be deferred in AR-inherited hyperinsulinism as it presents invariably as diffuse lesions. The emerging literature on genetic mechanisms in HH is expected to revolutionize the futuristic approach to its diagnosis and treatment.

Declaration of patient consent

The authors certify that they have obtained all appropriate patient consent.

Financial support and sponsorship

Nil.

Conflicts of interest

There are no conflicts of interest.

REFERENCES

1. Aynsley-Green A, Hussain K, Hall J, Saudubray JM, Nihoul-Fékété C, De Lonlay-Debeney P, *et al.* Practical management of hyperinsulinism in infancy. *Arch Dis Child Fetal Neonatal* Ed 2000;82:F98-107.
2. Arya VB, Senniappan S, Guemes M, Hussain K. Neonatal hypoglycemia. *Indian J Pediatr* 2014;81:58-65.
3. Straussman S, Levitsky LL. Neonatal hypoglycemia. *Curr Opin Endocrinol Diabetes Obes* 2010;17:20-4.
4. Menni F, de Lonlay P, Sevin C, Touati G, Peigné C, Barbier V, *et al.* Neurologic outcomes of 90 neonates and infants with persistent hyperinsulinemic hypoglycemia. *Pediatrics* 2001;107:476-9.
5. Tornovsky S, Crane A, Cosgrove KE, Hussain K, Lavie J, Heyman M, *et al.* Hyperinsulinism of infancy: Novel ABCC8 and KCNJ11 mutations and evidence for additional locus heterogeneity. *J Clin Endocrinol Metab* 2004;89:6224-34.
6. Sempoux C, Guiot Y, Jaubert F, Rahier J. Focal and diffuse forms of congenital hyperinsulinism: The keys for differential diagnosis. *Endocr Pathol* 2004;15:241-6.
7. Pizzoferrero M, Masselli G, Maiorana A, Casciani E, Sollaku S, Dionisi-Vici C, *et al.* PET/CT in congenital hyperinsulinism: Transforming patient's lives by molecular hybrid imaging. *Am J Nucl Med Mol Imaging* 2022;12:44-53.
8. Arimbawa IM, Satriawibawa IW, Ariyanta KD, Darmajaya IM, Anandasari PP, Maker LP. Neonatal congenital hyperinsulinism in Indonesia. *J Pediatr Surg Case Rep* 2021;64:101731. doi: 10.1016/j.epsc.2020.101731
9. Baş F, Darendeliler F, Demirkol D, Bundak R, Saka N, Günöz H. Successful therapy with calcium channel blocker (nifedipine) in persistent neonatal hyperinsulinemic hypoglycemia of infancy. *J Pediatr Endocrinol Metab* 1999;12:873-8.
10. Godin R, Taboada M, Kahn DJ. A comparison of the glycemic effects of glucagon using two dose ranges in neonates and infants with hypoglycemia. *J Perinatol* 2020;40:1841-9.
11. Arnoux JB, Verkarre V, Saint-Martin C,

- Montravers F, Brassier A, Valayannopoulos V, *et al.* Congenital hyperinsulinism: Current trends in diagnosis and therapy. *Orphanet J Rare Dis* 2011;6:63. doi: 10.1186/1750-1172-6-63
12. Bax KN, van der Zee DC. The laparoscopic approach toward hyperinsulinism in children. *Semin Pediatr Surg* 2007;16:245-51.
 13. Leibowitz G, Glaser B, Higazi AA, Salameh M, Cerasi E, Landau H. Hyperinsulinemic hypoglycemia of infancy (nesidioblastosis) in clinical remission: High incidence of diabetes mellitus and persistent beta-cell dysfunction at long-term follow-up. *J Clin Endocrinol Metab* 1995;80:386-92.
 14. Arya VB, Senniappan S, Demirbilek H, Alam S, Flanagan SE, Ellard S, *et al.* Pancreatic endocrine and exocrine function in children following near-total pancreatectomy for diffuse congenital hyperinsulinism. *PLoS One* 2014;9:e98054.
 15. Vannucci RC, Vannucci SJ. Hypoglycemic brain injury. *Semin Neonatol* 2001;6:147-55.
 16. Chandran S, Rajadurai VS, Haium AA, Hussain K. Current perspectives on neonatal hypoglycemia, its management, and cerebral injury risk. *Res Rep Neonatol* 2015;5:17-30.

How to cite this article: Sachin K, Balakrishnan U, Amboiram P, Agarwal P, Mahadevan S, Joseph LD. Challenges in the management of hyperinsulinemic hypoglycemia in a preterm neonate - A case report and literature review. *J Pediatr Endocrinol Diabetes* 2023;3:24-8.